URINARY TRACT

The urinary tract consists of the kidneys, ureters, urinary bladder, and urethra.

Kidneys:

The two kidneys function to excrete most of the waste products of metabolism. They play a major role in controlling the water and electrolyte balance within the body and in maintaining the acid-base balance of the blood. The waste products leave the kidneys as **urine,** which passes down the **ureters** to the **urinary bladder,** located within the pelvis. The urine leaves the body in the **urethra.**

Location and Description

The kidneys are reddish brown and lie behind the peritoneum high up on the posterior abdominal wall on either side of the vertebral column; they are largely under cover of the costal margin. The right kidney lies slightly lower than the left kidney because of the large size of the right lobe of the liver. With contraction of the diaphragm during respiration, both kidneys move downward in a vertical direction by as much as 1 in. (2.5 cm).

The **hilum** is a vertical slit in the medial concave border of each kidney that is bounded by thick lips of renal substance. The hilum extends into a large cavity called the **renal sinus.** The hilum transmits, from the front backward, the renal vein, two branches of the renal artery, the ureter, and the third branch of the renal artery (VAUA). Lymph vessels and sympathetic fibers also pass through the hilum.

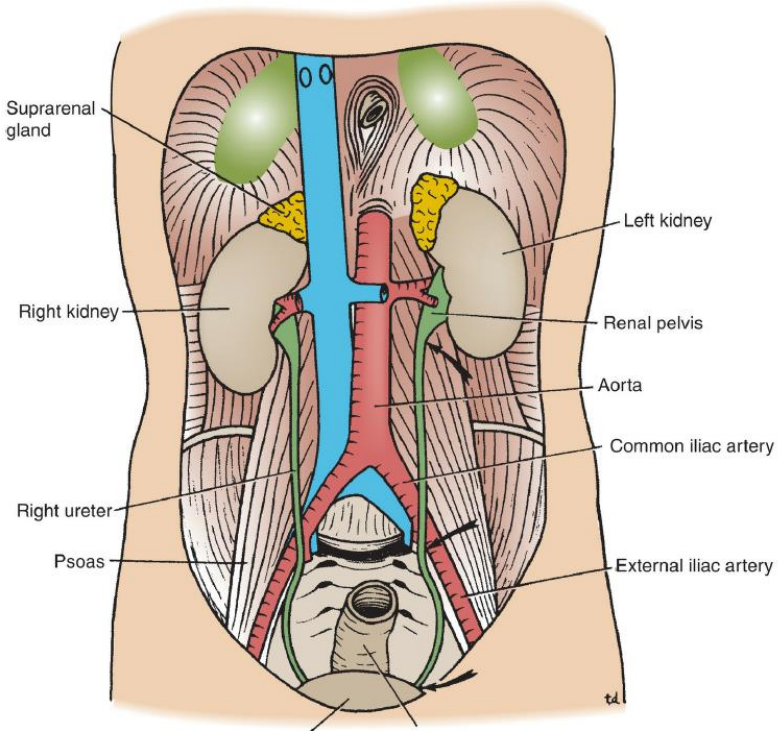

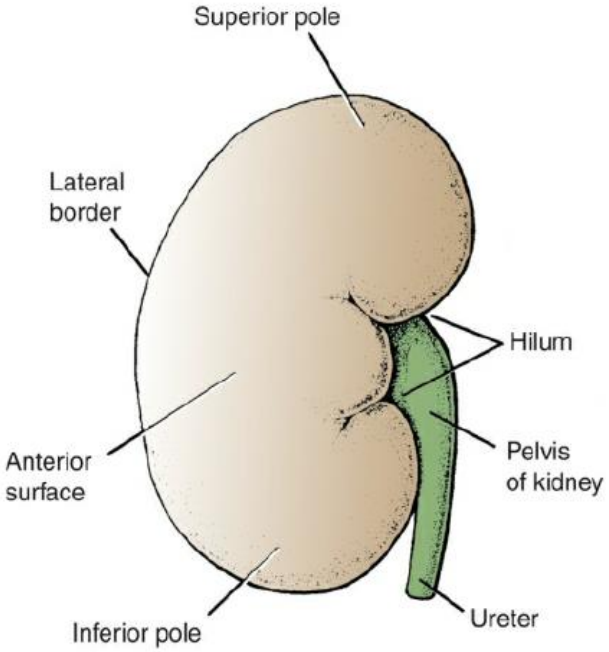

Coverings:

The kidneys have the following coverings

- **Fibrous capsule:** This surrounds the kidney and is closely applied to its outer surface.
- **Perirenal fat:** This covers the fibrous capsule.
- **Renal fascia:** This is a condensation of connective tissue that lies outside the perirenal fat and encloses the kidneys and suprarenal glands; it is continuous laterally with the transversalis fascia.
- **Pararenal fat:** This lies external to the renal fascia and is often in large quantity. It forms part of the retroperitoneal fat. The perirenal fat, renal fascia, and pararenal fat support the kidneys and hold them in position on the posterior abdominal wall.

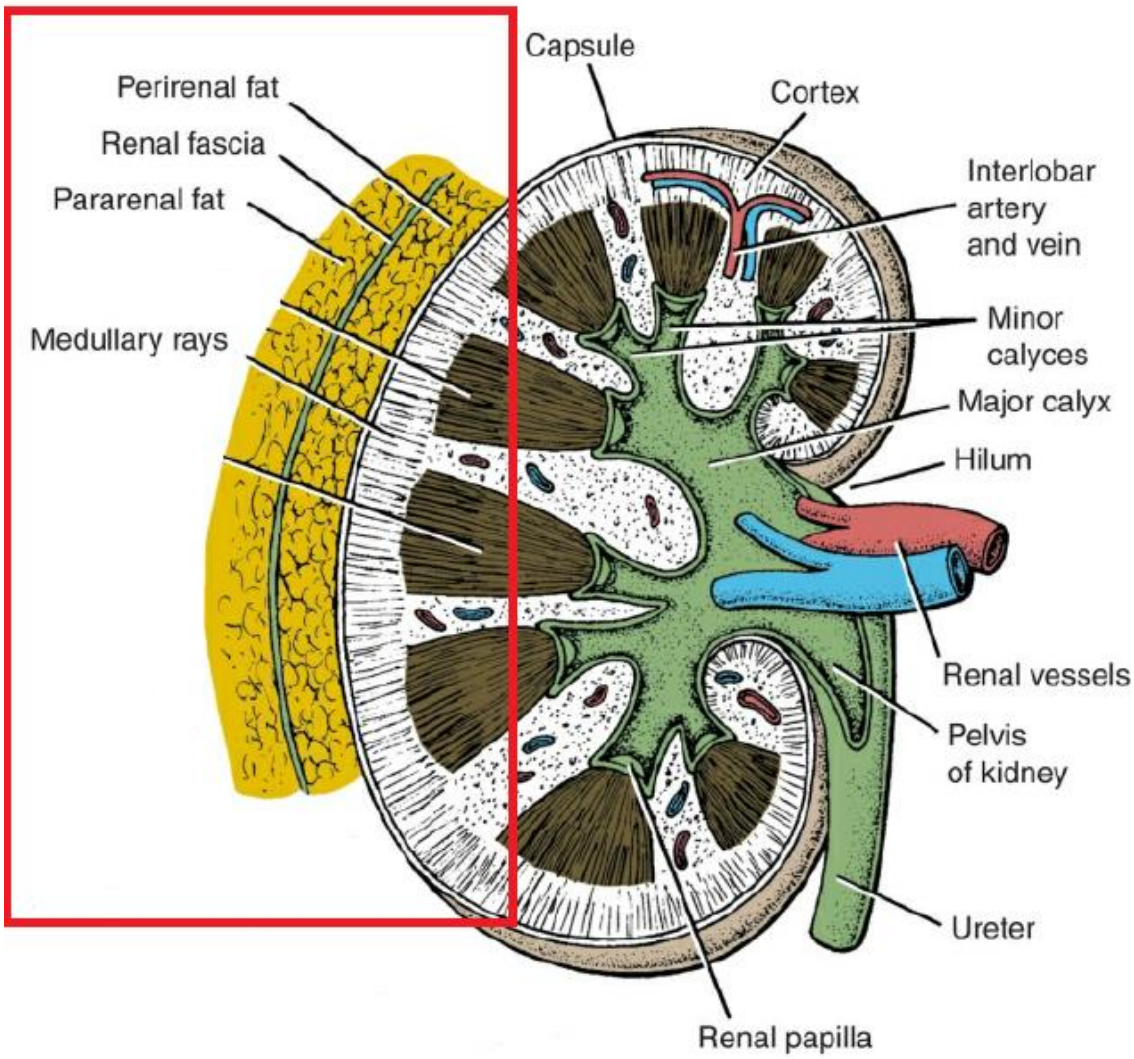

Renal Structure:

Each kidney has a dark brown outer **cortex** and a light brown inner **medulla**. The medulla is composed of about a dozen **renal pyramids**, each having its base oriented toward the cortex and its apex, the **renal papilla**, projecting medially. The cortex extends into the medulla between adjacent pyramids as the **renal columns**. Extending from the bases of the renal pyramids into the cortex are striations known as **medullary rays**.

The **renal sinus**, which is the space within the hilum, contains the upper expanded end of the ureter, the **renal pelvis**. This divides into two or three **major calyces**, each of which divides into two or three **minor calyces**. The apex of the renal pyramid, the **renal papilla**, indents each minor calyx.

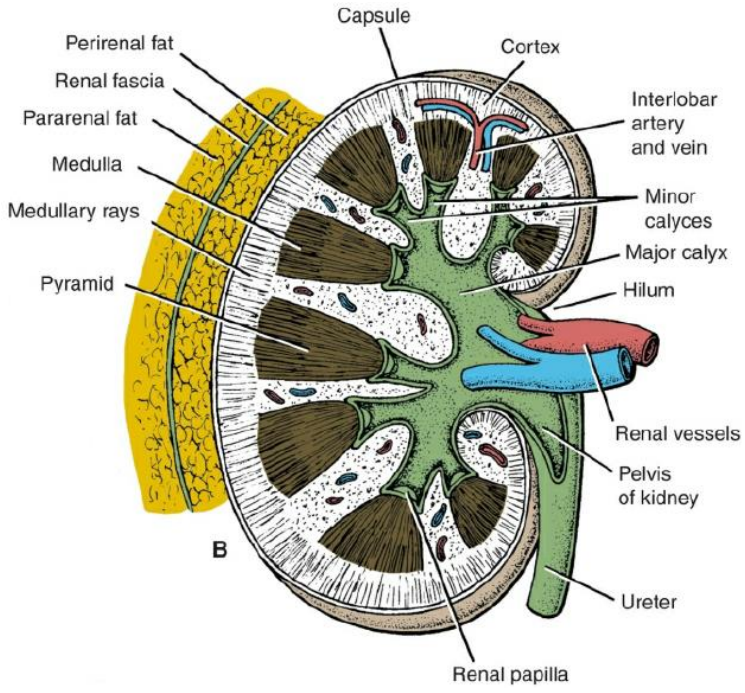

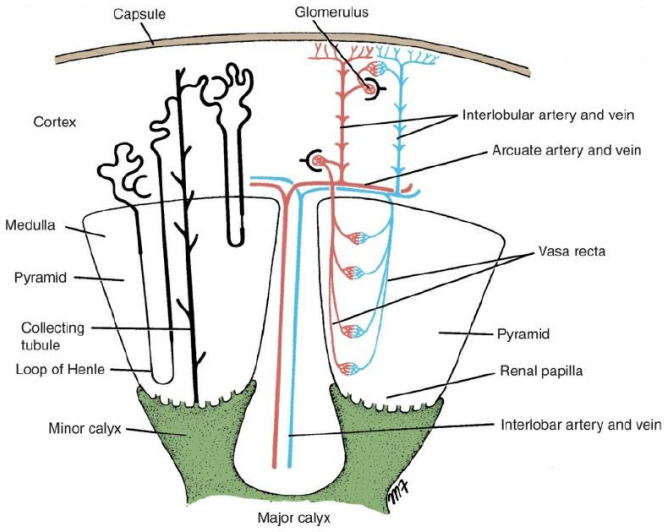

Important Relations, Right Kidney:

Note that many related structures are directly in contact with the kidneys, whereas visceral layers of peritoneum separate others.

- **Anteriorly:** The suprarenal gland, the liver, the second part of the duodenum, and the right colic flexure.
- **Posteriorly:** The diaphragm, the costodiaphragmatic recess of the pleura, the 12th rib, and the psoas, quadratus lumborum, and transversus abdominis muscles. The subcostal (Tl2), iliohypogastric, and ilioinguinal nerves (Ll) run downward and laterally.

Important Relations, Left Kidney:

- **Anteriorly:** The suprarenal gland, the spleen, the stomach, the pancreas, the left colic flexure, and coils of the jejunum.
- **Posteriorly:** The diaphragm, the costodiaphragmatic recess of the pleura, the 11th (the left kidney is higher) and 12th ribs, and the psoas, quadratus lumborum, and transversus abdominis muscles. The subcostal (T12), iliohypogastric, and ilioinguinal nerves (Ll) run downward and laterally.

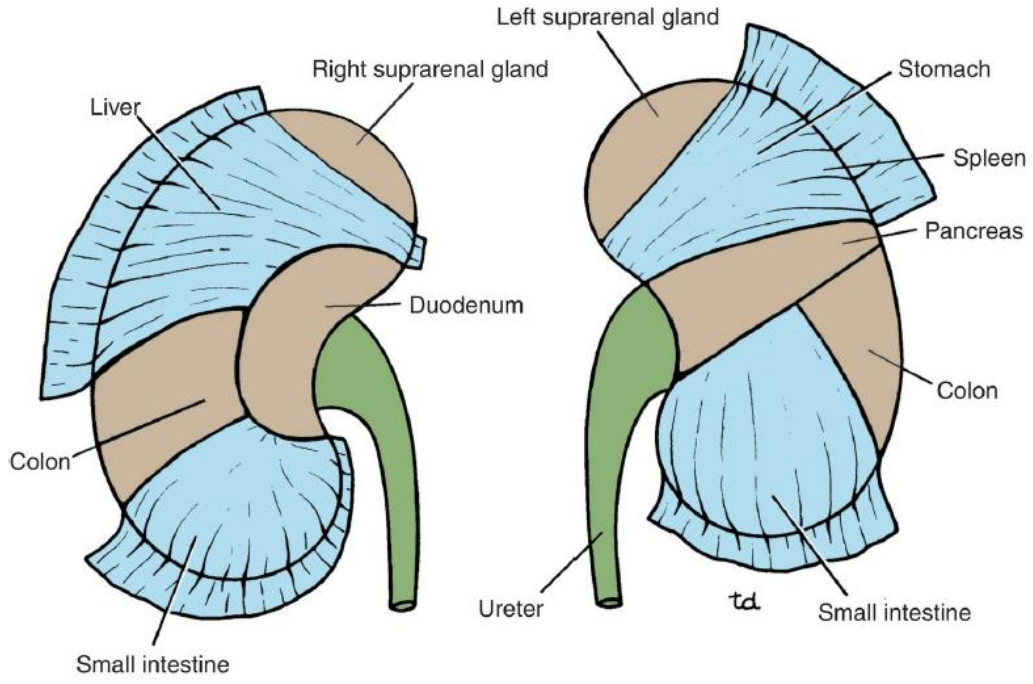

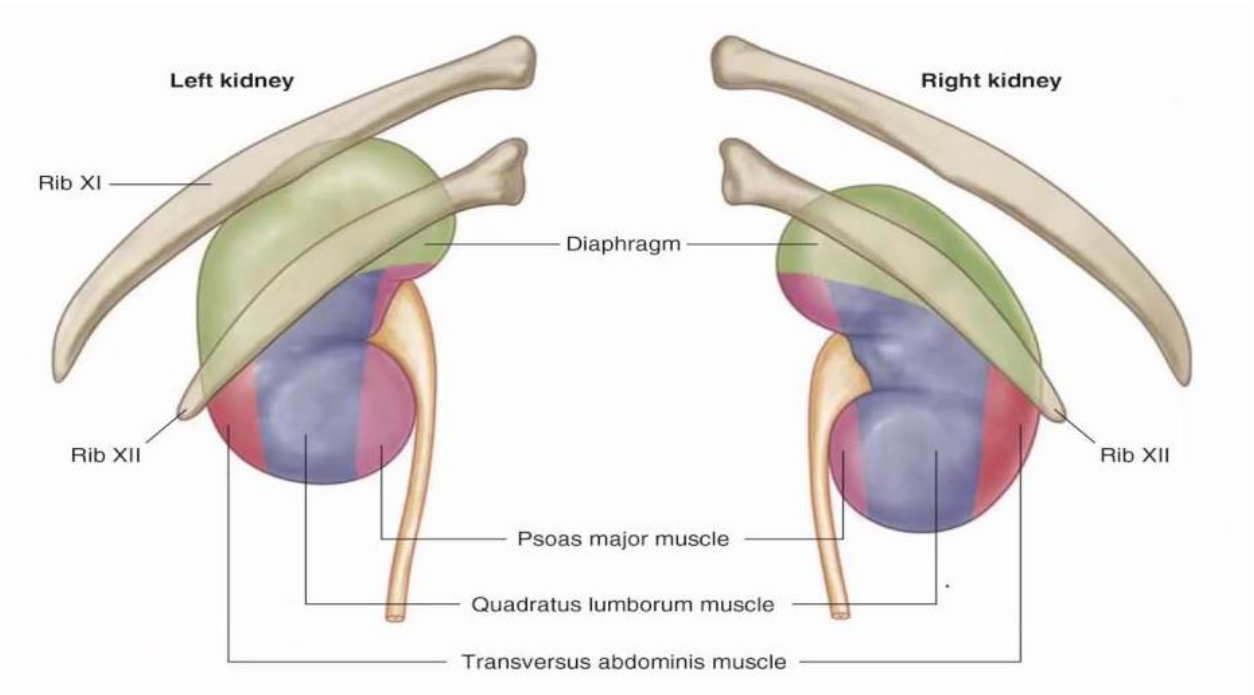

Blood Supply:

The renal artery arises from the aorta at the level of the second lumbar vertebra.

Each renal artery usually divides into five **segmental arteries** that enter the hilum of the kidney. They are distributed to different segments or areas of the kidney.

Lobar arteries arise from each segmental artery, one for each renal pyramid. Before entering the renal substance, each lobar artery gives off two or three **interlobar arteries** (see Fig. 7.64). The interlobar arteries run toward the cortex on each side of the renal pyramid. At the junction of the cortex and the medulla, the interlobar arteries give off the **arcuate arteries,** which arch over the bases of the pyramids. The arcuate arteries give off several **interlobular arteries** that ascend in the cortex. The **afferent glomerular arterioles** arise as branches of the interlobular arteries.

The **renal vein** emerges from the hilum in front of the renal artery and drains into the inferior vena cava.

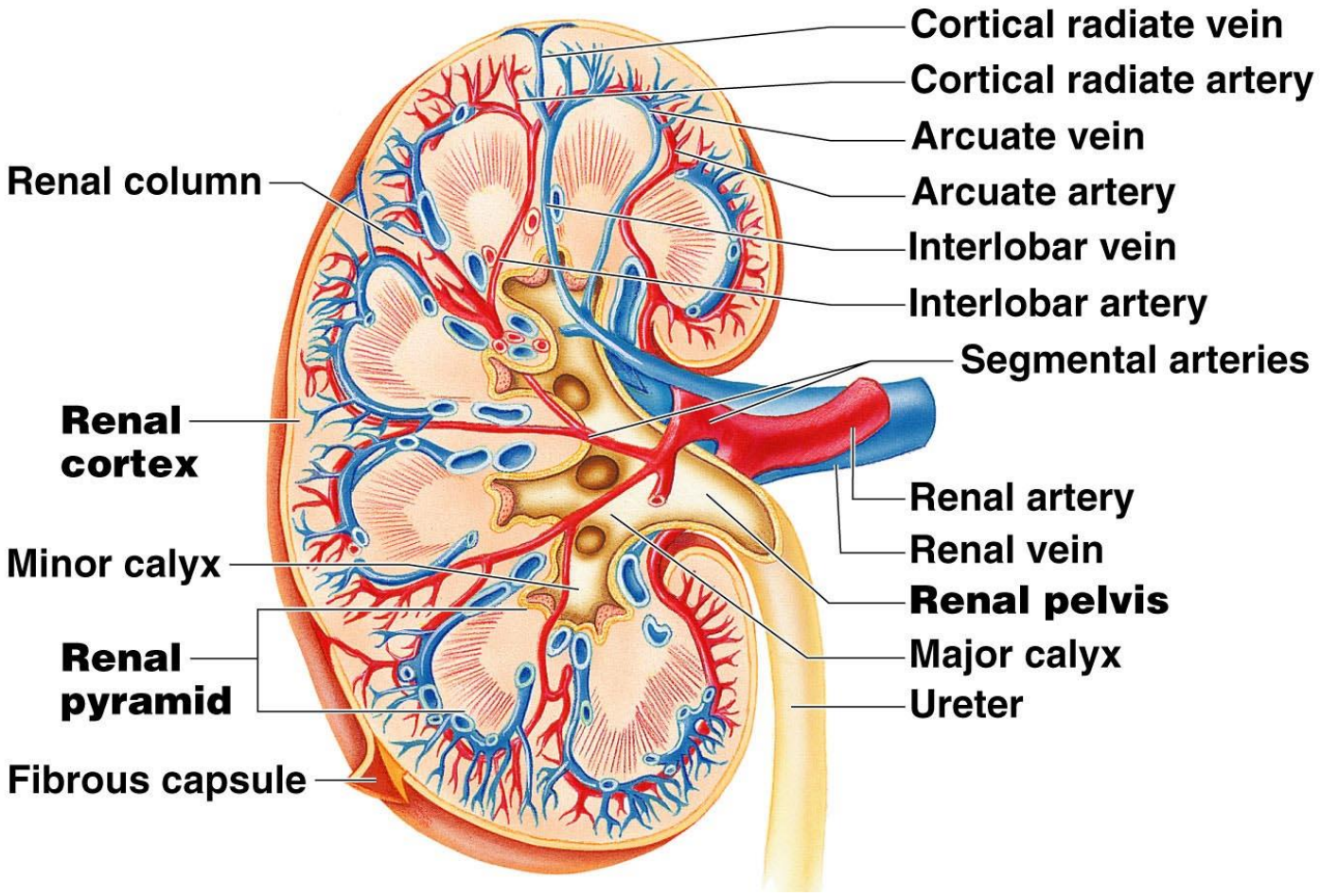

Lymph Drainage:
Lymph drains to the **lateral aortic lymph nodes** around the origin of the renal artery.

Nerve Supply:
The nerve supply is the renal sympathetic plexus. The afferent fibers that travel through the renal plexus enter the spinal cord in the 10th, 11th, and 12th thoracic nerves.

Ureter

The two ureters are muscular tubes that extend from the kidneys to the posterior surface of the urinary bladder. The urine is propelled along the ureter by peristaltic contractions of the muscle coat, assisted by the filtration pressure of the glomeruli. Each ureter measures about 10 in. (25 cm) long and resembles the esophagus (also 10 in. long) in having **three constrictions** along its course: where the renal pelvis joins the ureter, where it is kinked as it crosses the pelvic brim, and where it pierces the bladder wall.
The **renal pelvis** is the funnel-shaped expanded upper end of the ureter. It lies within the hilum of the kidney and receives the major calyces.
The ureter emerges from the hilum of the kidney and runs vertically downward behind the parietal peritoneum (adherent to it) on the psoas muscle, which separates it from the tips of the transverse processes of the lumbar vertebrae. It enters the pelvis by crossing the bifurcation of the common iliac artery In front of the sacroiliac joint. The ureter then runs down the lateral wall of the pelvis to the region of the Ischial spine and turns forward to enter the lateral angle of the bladder.

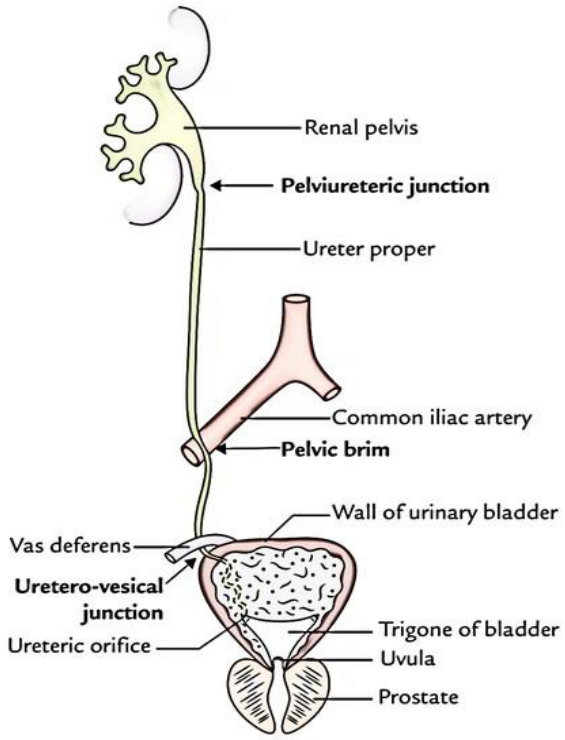

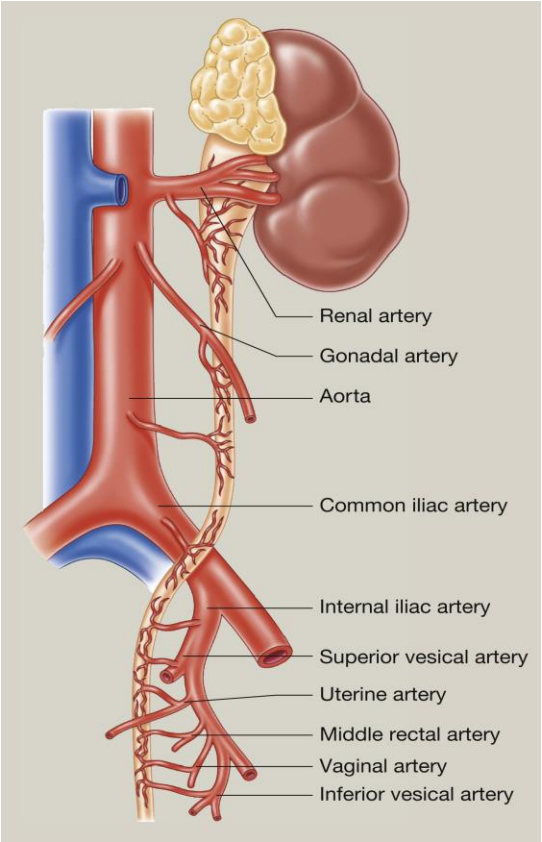

Relations, Right Ureter

• **Anteriorly:** The duodenum, the terminal part of the ileum, the right colic and ileocolic vessels, the right testicular or ovarian vessels, and the root of the mesentery of the small intestine.
• **Posteriorly:** The right psoas muscle, which separates it from the lumbar transverse processes, and the bifurcation of the right common mac artery.

Relations, Left Ureter

• **Anteriorly:** The sigmoid colon and sigmoid mesocolon, the left colic vessels, and the left testicular or ovarian vessels.
• **Posteriorly:** The left psoas muscle, which separates it from the lumbar transverse processes, and the bifurcation of the left common lilac artery.
• Medially: The Inferior mesenteric vein.

Blood Supply

The arterial supply to the ureter is as follows: upper end, **the renal artery**, middle portion, the **testicular or ovarian artery**; and in the pelvis, the **superior vesical artery**. Venous blood drains into veins that correspond to the arteries.

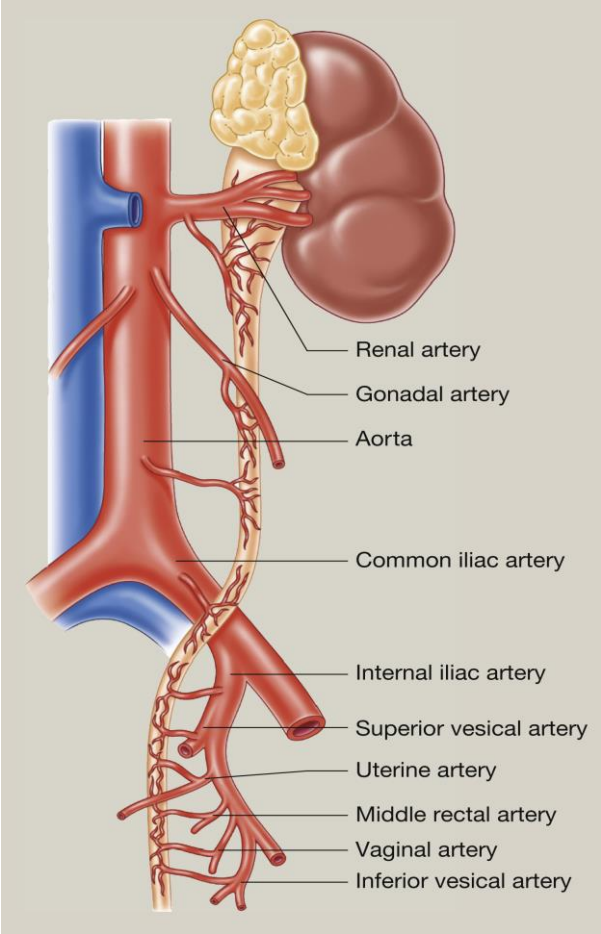

Lymph Drainage

The lymph drains to the lateral aortic nodes and the iliac nodes.

Nerve Supply

The nerve supply is the renal, testicular (or ovarian), and hypogastric plexuses (In the pelvis). Afferent fibers travel with the sympathetic nerves and enter the spinal cord in the first and second lumbar segments.